NIH RELAIS Document Delivery

NIH-10094376

NIH -- W1 NE3285

PAMELA GEHRON ROBEY
CSDB/NIDR/NIH Bldng 30 Rm 228
30 CONVENT DRIVE MSC 4320
BETHESDA, MD 20892

ATTN:		SUBMITTED:	2001-12-19 10:31:40
PHONE:	301-496-4563	PRINTED:	2001-12-21 10:24:44
FAX:	301-402-0824	REQUEST NO.:	NIH-10094376
E-MAIL:		SENT VIA:	LOAN DOC
			5335380

NIH Fiche to Paper Journal

TITLE:	NEUROLOGIA MEDICO-CHIRURGICA
PUBLISHER/PLACE:	Japan Neurosurgical Society Tokyo
VOLUME/ISSUE/PAGES:	1996 Feb;36(2):102-5 102-5
DATE:	1996
AUTHOR OF ARTICLE:	Kurimoto M; Endo S; Onizuka K; Akai T; Takaku A
TITLE OF ARTICLE:	Extradural optic nerve decompression for fibrous d
ISSN:	0470-8105
OTHER NOS/LETTERS:	Library does NOT report holding title
	0400775
	8907013
SOURCE:	PubMed
CALL NUMBER:	W1 NE3285
REQUESTER INFO:	AB424
DELIVERY:	E-mail: probey@DIR.NIDCR.NIH.GOV
REPLY:	Mail:

NOTICE: THIS MATERIAL MAY BE PROTECTED BY COPYRIGHT LAW (TITLE 17, U.S. CODE)

Neurol Med Chir (Tokyo) 36, 102~105, 1996

Extradural Optic Nerve Decompression for Fibrous Dysplasia with a Favorable Visual Outcome

—Case Report—

Masanori KURIMOTO, Shunro ENDO, Keiichiro ONIZUKA, Takuya AKAI, and Akira TAKAKU

Department of Neurosurgery, Toyama Medical and Pharmaceutical University, Toyama

Abstract

A 10-year-old boy with progressive left visual disturbance associated with craniobasal fibrous dysplasia underwent left frontotemporal craniotomy. Dysplastic lesions of the sphenoid ridge, orbital roof, anterior clinoid, and ethmoid sinus were removed through an extradural pterional approach and the optic nerve was completely decompressed. His vision was markedly improved postoperatively. Consecutive follow-up studies for 3 years have shown no deterioration of his visual acuity. Early optic nerve decompression is highly recommended to preserve visual function in patients with craniofacial fibrous dysplasia causing visual disturbance.

Key words: fibrous dysplasia, optic nerve decompression, skull base surgery

Introduction

Fibrous dysplasia is a developmental bone disease of unknown etiology, in which normal bone is replaced by fibro-osseous tissue. It may affect only one bone (monostotic form) or multiple bones (polyostotic form). The craniofacial bones are involved in 10% of patients with monostotic disease and 50% with the polyostotic form.[19] Ocular problems such as visual loss, diplopia, and proptosis occur in 20–35% of patients with craniofacial fibrous dysplasia.[11,13,19] The best treatment for the optic nerve lesions associated with fibrous dysplasia is surgery. However, in most cases the visual outcome after surgery was not satisfactory.

We present a patient with progressive visual disturbance associated with fibrous dysplasia, who underwent optic nerve decompression by the unilateral extradural approach and achieved a favorable visual outcome.

Case Report

A 10-year-old boy was hospitalized with progressive left visual disturbance. His visual acuity was 20/50 by the Snellen test 4 months before admission. However, on admission his vision had deteriorated to 20/500, but the visual field remained normal. A fundoscopic examination showed mild optic atrophy in the left eye. There was no facial asymmetry or proptosis of the eye balls.

Plain skull x-ray films showed smooth, homogeneous, and well-defined sclerosis in the left orbital roof and ethmoid sinus. Rhese-Goalwin's view showed narrowing of the left optic canal with surrounding dysplastic bone. Three-dimensional computed tomography (3D-CT) demonstrated enlargement of the left anterior clinoid process and planum sphenoidale (Fig. 1). Abnormal proliferation of the bone was present in the ethmoid sinus. These radiological findings suggested left optic nerve compression due to fibrous dysplasia.

A left frontotemporal craniotomy was performed to decompress the left optic nerve. The dysplastic sphenoid ridge was removed and the superior orbital fissure was opened through an extradural pterional approach. The fibrous dysplastic tissue was firm and hemorrhagic. The thickened orbital roof, anterior clinoid process, and ethmoid bone were drilled out with a high speed drill, and the optic nerve was completely decompressed (Fig. 2). There were no abnormal mor-

Received May 10, 1995; Accepted September 4, 1995

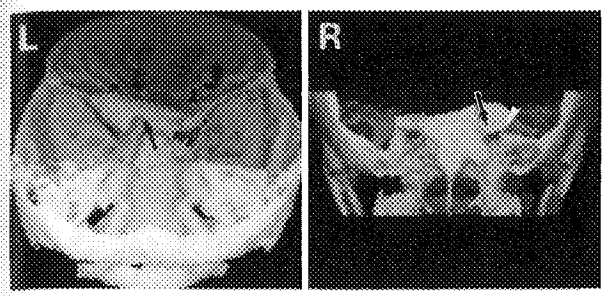

Fig. 1 Preoperative 3D-CT scans showing narrowing of the optic canal (*arrow*) and the superior orbital fissure (*arrowhead*), and enlargement of the left anterior clinoid process and the planum sphenoidale. Abnormal proliferation of bony tissue is seen in the ethmoid sinus.

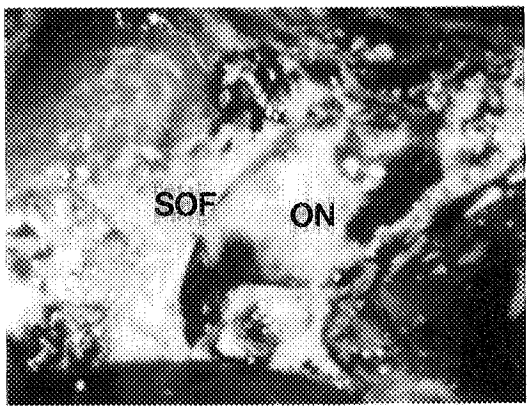

Fig. 2 Intraoperative photograph showing the decompressed optic nerve (ON) and superior orbital fissure (SOF).

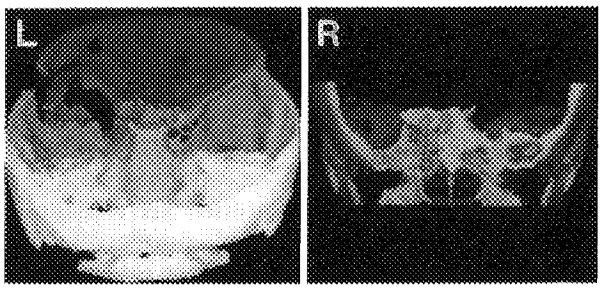

Fig. 3 Postoperative 3D-CT scans showing adequate decompression of the optic nerve. Dysplastic bone still remains at the inferomedial aspect of the left optic canal and in the ethmoid sinus.

phological changes of the left optic nerve sheath. The resulting bone defects in the left orbital roof and the lateral wall of the orbit were reconstructed using methyl methacrylate.

Histological examination of the surgical specimen revealed proliferation of fusiform fibroblasts and formation of irregular bony trabeculae. These findings confirmed the diagnosis of fibrous dysplasia.

His postoperative course was uneventful. Visual acuity improved immediately and became 20/100 2 months after surgery. Postoperative 3D-CT showed adequate decompression of the left optic nerve (Fig. 3). Although considerable fibrous dysplastic tissue remained in the ethmoid sinus, no progression of visual disturbance or CT evidence of increased dysplastic bone was detected during consecutive follow-up studies for 3 years.

Discussion

There is some controversy about the surgical treatment of craniofacial fibrous dysplasia. In the past, radical surgical procedures were avoided because of the poor cosmetic and functional results.[17] Surgery was warranted only in patients with either severe deformity or neurological symptoms. Partial resection to restore or maintain certain important functions such as vision during the active growth phase is advocated for most patients, because the lesion tends to stabilize in early adult life.[17,19] However, recent advances in craniofacial surgery and skull base surgery allow more aggressive and earlier surgical treatment.[4,7,11] Total excision and immediate reconstruction with autogenous bone graft may prevent both recurrence and malignant degeneration. However, even in the last decade, total excision of the lesion has rarely been possible in the central cranial base[2,4,10] and radical surgery has frequently caused greater functional loss than the disease process.[2,10,13] Chen and Noordhoff[3] recently proposed indications for the surgical treatment of craniomaxillofacial fibrous dysplasia, based on classification of the craniofacial bones into four major zones. Extensive excision and reconstruction should be restricted to the facial area (zone 1) and central cranial base lesions (zone 3) should be excised only when function is impaired or endangered.

Twenty-three patients with fibrous dysplasia and visual disturbance have been treated by decompressive surgery (Table 1).[1,4-6,8-13,15,16,18,19] Good postoperative visual acuity was not obtained in most patients, and in three visual acuity deteriorated after surgery.[6,13,19] These poor surgical results may be due to the long period of optic nerve compression and atrophic fundi before surgery. Only seven patients had dramatically improved vision postoperative-

Table 1 Patients with fibrous dysplasia and visual disturbance treated by decompressive surgery

Case No.	Author (Year)	Age/ Sex	Preoperative visual acuity	Preoperative optic fundus	Operative result	Remarks
1	Sassin and Rosenberg (1968)[19]	10/F	20/200	atrophy	no change	
2		19/M	20/70	atrophy	no change	
3		67/F	20/70	papilledema	improved	
4		43/F	20/20	normal	deteriorated	
5		15/F	20/20	normal	no change	
6	Calderon and Brady (1969)[1]	11/F	20/25	normal	no change	
7	Finney and Roberts (1976)[6]	19/M	not described	not described	deteriorated	
8	Liakos *et al.* (1979)[11]	20/F	blind	normal	no change	large mucocele in sphenoid sinus
9	Mochimatsu *et al.* (1983)[12]	49/M	20/500	pale	improved	
10	Edgerton *et al.* (1985)[4]	18/F	not described	normal	improved	
11	Lello and Sparrow (1985)[10]	16/M	not described	not described	improved	
12	Moore *et al.* (1985)[13]	7/M	not described	normal	no change	
13		7/M	not described	atrophy	deteriorated	
14		12/F	not described	normal	no change	
15		9/M	not described	normal	no change	
16		15/F	not described	atrophy	no change	
17	Feldman *et al.* (1986)[5]	34/F	20/400	not described	improved	mucocele in fronto-ethmoid sinus
18	Osguthorpe and Gudeman (1987)[15]	21/F	light perception	atrophy	improved	
19	Kurokawa *et al.* (1989)[9]	11/M	light perception	normal	improved	occlusion of ophthalmic artery
20	Saito *et al.* (1990)[18]	4/F	light perception	atrophy	no change	
21	Posnic *et al.* (1993)[16]	3/M	light perception	atrophy	no change	
22	Jan *et al.* (1994)[8]	8/M	hand movements	atrophy	no change	
23	Present case	10/M	20/50	atrophy	improved	

ly.[4,5,9,10,12,15,19] In these patients, direct compression of the optic nerve had caused visual disturbance but severe optic atrophy had not occurred. In some patients, accompanying nasal mucocele or hemorrhage into the involved tissue may have been the cause of rapid visual disturbance.[5,9] These patients showed rapid improvement of vision after surgery. The optic nerve is susceptible to compression and ischemia, so once severe loss of visual acuity occurs, visual outcome after surgery will be poor. Therefore, surgery should be performed before optic atrophy occurs.

Different approaches have been used for optic nerve decompression for craniofacial fibrous dysplasia. The intradural and combined intradural and extradural approaches provide good orientation and allow complete tumor excision.[8,12,13,15] However, these approaches may cause complications such as cerebrospinal fluid (CSF) leakage or damage to the susceptible optic nerve.[8,13] The extradural approach is less invasive for the compressed nerve. Saito *et al.*[18] emphasized that the bilateral optic nerves could be decompressed without CSF leakage or damage to the brain using a purely extradural approach. Munro[14] suggested that use of the high speed drill risks transmitting thermal energy to the brain and nerves. The extradural approach might transmit less such thermal energy to the optic nerve than the intradural approach. However, skillful microneurosurgical techniques are required using either approach to prevent neurological complications.

We recommend that surgical treatment of craniofa-

cial fibrous dysplasia with visual disturbance should be undertaken as early as possible. Visual improvement can be expected if the optic fundi are not atrophic.

References

1) Calderon M, Brady HR: Fibrous dysplasia of bone with bilateral optic foramina involvement. *Am J Ophthalmol* 68: 513–515, 1969
2) Camilleri AE: Craniofacial fibrous dysplasia. *J Laryngol Otol* 105: 662–666, 1991
3) Chen Y-R, Noordhoff MS: Treatment of craniomaxillofacial fibrous dysplasia: How early and how extensive? *Plast Reconstr Surg* 86: 835–842, 1990
4) Edgerton MT, Persing JA, Jane JA: The surgical treatment of fibrous dysplasia with emphasis on recent contributions from cranio-maxillo-facial surgery. *Ann Surg* 202: 459–479, 1985
5) Feldman MD, Rao VM, Lowry LD, Kelly M: Fibrous dysplasia of the paranasal sinuses. *Otolaryngol Head Neck Surg* 95: 222–225, 1986
6) Finney HL, Roberts TS: Fibrous dysplasia of the skull with progressive cranial nerve involvement. *Surg Neurol* 6: 341–343, 1976
7) Jackson IT, Hide AH, Gomuwka PK, Laws ER Jr, Langford K: Treatment of cranio-orbital fibrous dysplasia. *Journal of Maxillofacial Surgery* 10: 138–141, 1982
8) Jan M, Dweik A, Destrieux C, Djebbari Y: Fronto-orbital sphenoidal fibrous dysplasia. *Neurosurgery* 34: 544–547, 1994
9) Kurokawa Y, Sohma T, Tsuchita H, Kitami K, Suzuki S, Sohma K: Hemorrhage into fibrous dysplasia following minor head injury. Effective decompression for the ophthalmic artery and optic nerve. *Surg Neurol* 32: 421–426, 1989
10) Lello GE, Sparrow OC: Craniofacial polyostotic fibrous dysplasia. *Journal of Maxillofacial Surgery* 13: 267–272, 1985
11) Liakos GM, Walker CB, Carruth JAS: Ocular complications in craniofacial fibrous dysplasia. *Br J Ophthalmol* 63: 611–616, 1979
12) Mochimatsu Y, Kuwana N, Fujino H: Transfrontal optic canal decompression to treat visual involvement in craniofacial fibrous dysplasia. Case report. *Neurol Med Chir (Tokyo)* 23: 227–232, 1983 (in Japanese)
13) Moore AT, Buncic JR, Munro IR: Fibrous dysplasia of the orbit in childhood. *Ophthalmology* 92: 12–20, 1985
14) Munro IR: Discussion. Treatment of craniomaxillofacial fibrous dysplasia: How early and how extensive? *Plast Reconstr Surg* 86: 843–844, 1990
15) Osguthorpe JD, Gudeman SK: Orbital complications of fibrous dysplasia. *Otolaryngol Head Neck Surg* 97: 403–405, 1987
16) Posnic JC, Wells MD, Drake JM, Buncic JR, Armstrong D: Childhood fibrous dysplasia presenting as blindness: A skull base approach for resection and immediate reconstruction. *Pediatr Neurosurg* 19: 260–266, 1993
17) Ramsey HE, Strong EW, Frazell EL: Fibrous dysplasia of the craniofacial bones. *Am J Surg* 116: 542–547, 1968
18) Saito K, Suzuki Y, Nehashi K, Sugita K: Unilateral extradural approach for bilateral optic canal release in a patient with fibrous dysplasia. *Surg Neurol* 34: 124–128, 1990
19) Sassin JF, Rosenberg RN: Neurological complications of fibrous dysplasia of the skull. *Arch Neurol* 18: 363–369, 1968

Address reprint requests to: M. Kurimoto, M.D., Department of Neurosurgery, Toyama Medical and Pharmaceutical University, 2630 Sugitani, Toyama 930–01, Japan.