Arch Orthop Trauma Surg (2000) 120:460–464

© Springer-Verlag 2000

CURRENT PROBLEM CASE

L. T. C. Chow · J. Griffith · W. H. Chow
S. M. Kumta

Monostotic fibrous dysplasia of the spine: report of a case involving the lumbar transverse process and review of the literature

Received: 22 April 1999

Abstract Monostotic fibrous dysplasia of the spine is rare. We report its clinical, radiologic and histologic features affecting a 47-year-old housewife. She presented with low-back pain of 1-year's duration, and radiographs showed a diffuse expansile lesion in the left transverse process of the fourth lumbar vertebra. The lesion was excised and histologically confirmed to be fibrous dysplasia. The patient remained well 8 years after operation. Including the present case, a total of 22 cases of monostotic fibrous dysplasia of the spine were found in the literature. Combining these reported cases, we found that the condition affects either sex with equal frequency and presents at any age, the mean being 32 years. There is no predilection for any part of the spinal column, though sacral or coccygeal involvement is distinctly rare. It most commonly involves the body and adjacent pedicle, although no part of the vertebra is spared. It is worth noting that a propensity for progressive enlargement, even to the extent of causing graft destruction, exists if the lesion is left untreated or incompletely treated. Complete removal of all involved bone, together with stabilization, should therefore be the treatment of choice for this condition.

L. T. C. Chow (✉)
Department of Anatomical and Cellular Pathology,
Prince of Wales Hospital, 30-32, Ngan Shing Street,
Shatin, Hong Kong
e-mail: lchow@cuhk.edu.hk,
Tel.: +852-26322335, Fax: +852-26376274

J. Griffith
Department of Diagnostic Radiology and Organ Imaging,
Prince of Wales Hospital, Hong Kong

W. H. Chow
Department of Medicine, Grantham Hospital, Hong Kong

S. M. Kumta
Department of Orthopaedics and Traumatology,
Prince of Wales Hospital, Hong Kong

Introduction

In 1938, Lichtenstein coined the term polyostotic fibrous dysplasia for a developmental anomaly characterised by replacement of the medulla of bone by fibrous tissue containing poorly organised trabeculae of immature bone [12]. In a later study in 1942, Lichtenstein and Jaffe recognised that this disorder can affect either single or multiple bone [13], corresponding to the monostotic and polyostotic varieties of the disease. They also noticed the association of the more severely affected polyostotic cases with abnormal skin pigmentation, precocious puberty, hyperthyroidism and other extra-skeletal abnormalities. Although any bone in the body can be affected, spinal involvement is seen mostly in the polyostotic form and is distinctly unusual in the monostotic variety [6]. For instance, in the series of 67 cases of monostotic fibrous dysplasia reported by Schlumberger in 1946, only 1 involved the cervical vertebra [25], and in the 50 cases reported by Henry in 1969, the spine was never affected [7].

In this article, we report a patient with monostotic fibrous dysplasia affecting the left transverse process of the fourth lumbar vertebra. The literature is reviewed to delineate the clinical, radiologic, and pathologic features of monostotic fibrous dysplasia of the spine.

Case report

A 47-year-old housewife presented to her doctor because of low-back pain of 1 year's duration. She was diagnosed as suffering lumbar spondylosis and treated with analgesics. However, the pain persisted, and she was thus referred to our outpatient clinic. Physical examination revealed no abnormality apart from mild tenderness in the lower lumbar region of the back.

A lumbar spine radiograph showed, in conjunction with mild degenerative changes, diffuse expansion of the fourth lumbar transverse process on the left side (Fig. 1). Computed tomography confirmed expansion of the transverse process with no cortical destruction or extraosseous mass (Fig. 2).

Based on the clinical and radiologic findings, the differential diagnosis included osteoblastoma, giant cell tumor, monostotic fibrous dysplasia, aneurysmal bone cyst and chronic infection, no-

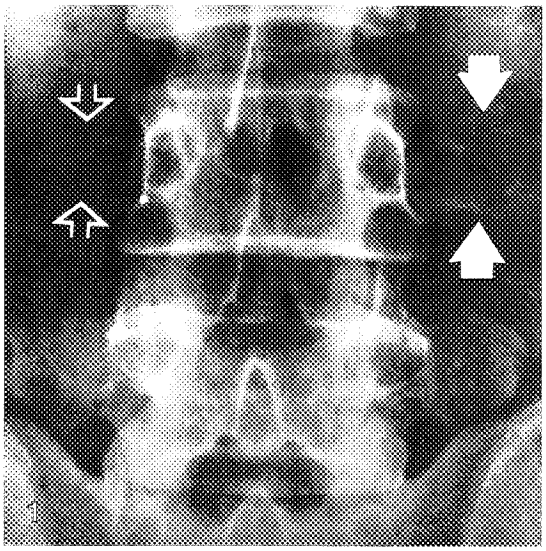

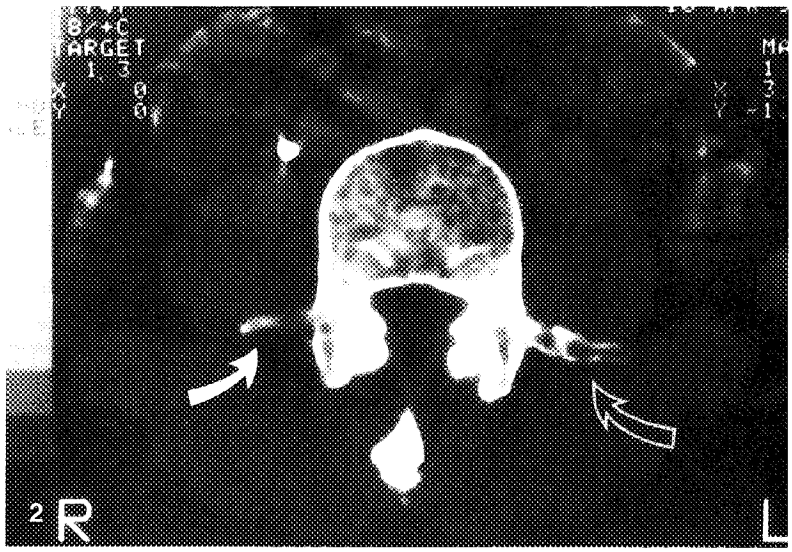

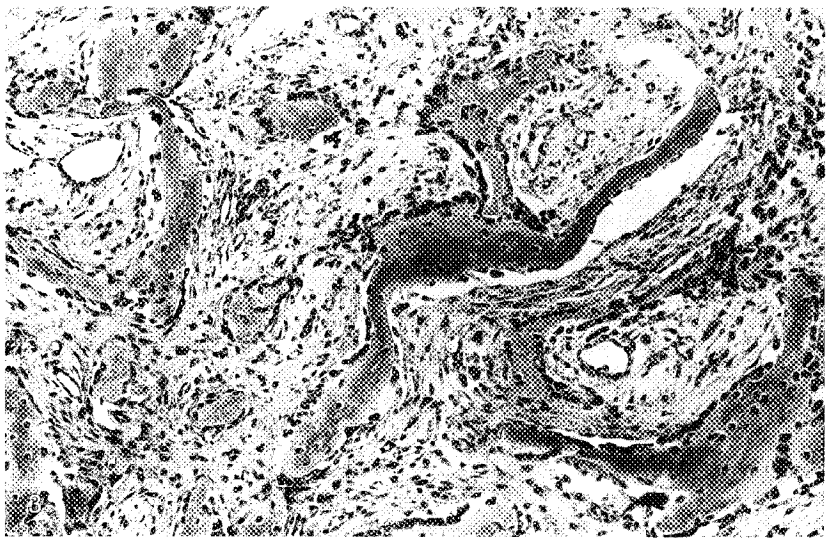

Fig. 1 Anteroposterior view of lower lumbar region showing expansion of the left transverse process of fourth lumbar vertebra *(arrows)* relative to opposite side *(open arrows)*. A ground glass matrix cannot be appreciated

Fig. 2 Axial computed tomogram of the fourth lumbar vertebra (bone window), showing expansion of the left transverse process *(open arrow)* relative to the opposite side *(arrow)*. Note the thick rim of perilesional sclerosis medially, the lack of any cortical destruction or extraosseous extension

Fig. 3 Histologically, the lesion consists of many narrow, curved, and irregularly shaped trabeculae of woven bone embedded in a moderately cellular fibrous tissue background (hematoxylin and eosin, × 50)

tably tuberculosis. The left transverse process of the fourth lumbar vertebra was excised.

The excised specimen consisted of bony tissue, 3 × 2 × 1.5 cm in maximal dimension. Its cut section showed pale grey, firm tissue with a gritty consistency, bordered by a thin layer of cortical bone in most areas. The lesion showed a uniform histologic appearance, with many narrow, curved, and irregularly shaped trabeculae of woven bone embedded in a moderately cellular fibrous tissue background (Fig. 3). Most of the osteoid contained interspersed osteoblasts and appeared to emerge from the surrounding fibrous background. Osteoblastic rimming along the bony trabeculae was inconspicuous and seen only focally. The fibro-osseous tissue infiltrated between trabeculae of normal bone at the periphery of the lesion. The resection margins were clear.

The overall features were those of fibrous dysplasia of the left transverse process of the fourth lumbar vertebra, which was completely excised. The patient remains well 8 years after excision.

Discussion

Since the first description of fibrous dysplasia by Lichtenstein in 1938 [12], it has been recognised as a relatively common benign disease of childhood, characterised by the replacement of the medullary component of one or, less commonly, several bones with fibroblastic tissue containing irregularly shaped metaplastic woven bone, and accounts for about 7% of benign bone tumors [3, 4, 19]. The exact etiology remains unknown, but the monostotic form is seven times more common than the polyostotic variant, and occurs with equal frequency in both sexes [4]. It is a disease of children or young adults which usually neither regresses nor enlarges after cessation of bone growth [3, 4, 7, 19]. Malignant transformation is distinctly uncommon [9, 21, 28, 31].

Vertebral involvement in fibrous dysplasia is extremely rare, especially in the monostotic variant. Several large series have failed to detect any case of monostotic fibrous dysplasia of the spine [3, 4, 7, 19]. Indeed, the present patient represents the only case of spinal involvement among 32 cases of monostotic fibrous dysplasia found in the surgical pathology file of our hospital from 1984 to 1997. The rarity of this condition prompted us to review the literature on the reported cases of monostotic fibrous dysplasia of the spine. A total of 18 reports, comprising

Table 1 Details of reported cases of monostotic fibrous dysplasia of the spine (*C* cervical, *T* thoracic, *L* lumbar, *NA* not available)

Reports	Sex	Age (years)	Level (location)/laterality	Symptoms/duration	Treatment/outcome
Schlumberger, 1946 [25]	M	20	C4 (body)	Post-traumatic/ 11 months	Biopsy/NA
Ledoux-Lebard, 1953 [11]	F	58	L1 (body, pedicle)/NA	Myelopathy/6 years	Biopsy & decompression/NA
Rosendahl-Jensen, 1956 [23]	F	35	C4 (body, articular, transverse & spinous processes)/left	Post-traumatic pain/ 1 year	Curettage/ well, 1 year
Harris, 1962 [6]	M	42	L4 (transverse process)/right	Pain/NA	Biopsy/pain, 4 years
Daniluk, 1979 [1]	F	28	L4 (articular & transverse processes)/right	Pain/10 years	Excision/well
Resnik, 1984 [20]	F	27	C6 (body, pedicle, lamina)/right	Post-traumatic pain/acute	Biopsy/NA
Rosenblum, 1987 [22]	M	20	T1 (body, pedicle, articular process, lamina)/right	Post-traumatic/acute	Excision & fusion/well
Nigrisoli, 1987 15]	F	36	L3 (body)	Pain/3 years	Curettage & fusion/ pain, 14 months
Kahn, 1988 [10]	M	23	L3 (body, pedicle, transverse process, lamina)/right	Post-traumatic pain/ 2 years	Excision & fusion/ well
Troop, 1988 [29]	F	12	L3 (body, articular & transverse processes)/right	Post-traumatic/acute	Curettage & fusion/ well, 3 years
Wright, 1988 [30]	NA NA	NA NA	C2 (spinous process) C5 (lamina)/NA	NA/NA NA/NA	NA/NA NA/NA
Hu, 1990 [8]	M	41	C2 (body, pedicle, lamina, odontoid, transverse & spinous processes)/right	Pain/6 months	Curettage & fusion/ well, 2.5 years
Ohki, 1990 [16]	F M	20 31	C2 (spinous process) L5 (body, pedicle, lamina)/left	Tumor mass/2 months Pain/2 years	Curettage/well, 5 years Excision & fusion/ well, 1 year
Singer, 1991 [26]	F	44	T11 (body)	Pain/1 week	Excision & fusion/ well, 2 years
Ehara, 1992 [2]	M F	19 NA	C1 (lateral mass)/left L3 (body)	Asymptomatic Pain/NA	NA/NA NA/NA
Nabarro, 1994 [14]	F	46	T7 (body, pedicle, lamina, transverse process)/right	Pain/6 weeks	Excision & fusion/ well, 6 months
Penrod, 1996 [17]	F	40	T3 (body, pedicle)/right	Pain/9 months	Excision/well
Przybylski,1996 [18]	M	12	T5 (body, pedicle, lamina, transverse process)/right	Myelopathy/2 weeks	Excision & fusion/ well, 1.5 years
Present case	F	47	L4 (transverse process)/left	Pain/1 year	Excision/well, 8 years

Table 2 Summary of reported cases of monostotic fibrous dysplasia of the spine ($n = 22$)

Sex	Age (years)	Level	Location	Symptoms (duration)	Treatment (outcome)
8 M	Range 12–58	8/22 cervical	15/22 body	6/20 post-traumatic pain (acute-2 years)	9/18 excision (well, up to 8 years)
12 F	Median 31	5/22 thoracic	9/22 pedicle	10/20 pain (1 week-10 years)	5/18 curettage (4 well, 1–5 years; 1 pain at 14 months)
2 NA	Mean 32	9/22 lumbar	8/22 lamina 4/22 articular process	2/20 myelopathy (2 weeks-6 years) 1/20 tumor mass	4/18 biopsy (1 pain at 4 years; 3 NA)
			9/22 transverse process 4/22 spinous process 1/22 lateral mass	1/20 asymptomatic 2 NA	4 NA

21 cases, describing the clinical presentation and treatment have been published [1, 2, 6, 8, 10, 11, 14, 15, 16, 17, 18, 20, 22, 23, 25, 26, 29, 30], the details of which are summarised in Table 1. Although reviews and summaries of the literature are included in some reports [8, 17, 18, 22], they either contain only earlier cases [8, 22] or else are incomplete [17, 18]. In providing an updated review of the reported cases of monostotic fibrous dysplasia of the spine, we have sought to explore, in particular, whether a predilection exists for any spinal level or vertebral location, whether there are any typical presenting symptoms, what types of treatment are given, and what are the subsequent clinical outcomes of this condition. The relevant data are summarised in Table 2.

Including the present case, a total of 22 cases of monostotic fibrous dysplasia of the spine were studied. There

were 8 men and 12 women (the sex of two patients was not provided in the series reported by Wright and Stoker [30]). Their ages ranged from 12 to 58 years, with a median and mean of 31 and 32 years, respectively (Table 2). At presentation, 16 patients complained of pain (precipitated by trauma in 6 instances), 2 suffered from symptoms of spinal cord compression, one noticed the presence of a tumor mass, and one was asymptomatic. The duration of symptoms ranged from a week to years (Table 2).

Of the 22 cases of monostotic fibrous dysplasia of the spine, 8 involved cervical, 5 thoracic, and 9 lumbar vertebra. Although there have been no reports specifying sacral or coccygeal involvement, in the series of 296 cases of monostotic fibrous dysplasia published in the textbook by Schajowicz [24], the only case of spinal involvement was in the sacrum, detailed clinical information of which is not given. In 11 cases, vertebral involvement was extensive, affecting both the body and variable contiguous portions of the posterior elements. In one case [2], the left lateral mass of the altas (the first cervical vertebra) was affected, and in another, both the right articular and transverse processes of the fourth lumbar vertebra, but not the body, were involved [1]. Elsewhere in the spine, there was isolated involvement of the vertebral body in 4 cases, the transverse process in 2, the lamina in 1, and the spinous process in 2. The body is most frequently affected (15 out of the 22 cases), probably because it constitutes the large majority of the vertebral mass. Furthermore, due to their close anatomic relationship, involvement of the pedicle (9 cases) was invariably associated with concomitant involvement of the body. Another point of interest is that, for no apparent reason, the right side was affected in 10 out of the 14 patients with posterior element disease where laterality was stated.

Radiologically, the features of monostotic fibrous dysplasia of the spine are similar to the extraspinal lesions, characterised by medullary expansion, ground glass matrix, narrow zone of transition and a variable degree of marginal sclerosis.

The histologic features of monostotic fibrous dysplasia of the spine conform to the typical lesions seen in extraspinal locations, consisting of narrow, curved, and misshapen, woven bony trabeculae, supported in a background of fibroblastic tissue of variable cellularity. Osteoblastic rimming is inconspicuous. The woven bone is considered metaplastic because it contains interspersed osteoblasts and appears to emerge from the surrounding fibroblastic background. Furthermore, this woven bone never becomes transformed to lamellar bone, suggesting that the process of bone formation is arrested at an early stage resembling membranous ossification. Ultrastructurally, the immature woven bony trabeculae are lined by abnormal osteoblasts with a fibroblast-like appearance [5].

The extreme rarity of this disorder and the lack of detailed reports of long-term follow-up renders study of the natural behavior and comparison of the different treatment modalities difficult. However, evidence does suggest that, in contrast to the conventional belief of cessation of growth after puberty, monostotic fibrous dysplasia of the spine may continue to grow in skeletally mature patients. For example, three patients, aged 35, 23, and 40 years, developed radiographic evidence of progressive bony destruction, 2 months [23], 2 years [10], and 10 months [17], respectively, after recognition of their disease but before commencement of therapy. Furthermore, two patients, including the second with radiographic progression, developed increasing pain and new neurologic deficits within 6 weeks of a diagnostic biopsy [10, 14]. It is also worth noting that there are reports describing progressive involvement of bone grafts [6] or adjacent bony elements [26] when incomplete resection was performed. Incomplete resection and/or inadequate stablilization may result in a less favorable outcome. Of the 4 patients undergoing biopsy without subsequent excision, the only one for which follow-up information is available suffered from persistent pain after 4 years [6]. In contrast, all 9 patients (including our present case with the longest period of follow-up of 8 years) treated with aggressive resection of their lesions with or without spinal fusion remained well after the operation. The existing evidence therefore supports the concept that, in common with extraspinal lesions [27], aggressive resection and stabilization form the treatment of choice in monostotic fibrous dysplasia of the spine.

In conclusion, monostotic fibrous dysplasia of the spine, though very rare, can affect either sex with equal frequency and present at any age, the mean being 32 years. It most commonly involves the body and adjacent pedicle, though it can affect any part of the vertebra. No particular predilection for a part of the spinal column exists, although sacral or coccygeal involvement is distinctly rare. We particularly emphasize its propensity to enlarge if untreated or incompletely treated, even to the extent of causing graft destruction. Complete removal of all involved bone coupled with stabilization should thus be the treatment of choice.

References

1. Daniluk A, Witwicki T (1979) A case of fibrous dysplasia of the spine. Chir Narzadow Ruchu Ortop Pol 44:165–167
2. Ehara S, Kattapuram SV, Rosenberg AE (1992) Fibrous dysplasia of the spine. Spine 17:977–979
3. Firat D, Stutzman L (1968) Fibrous dysplasia of the bone: review of twenty-four cases. Am J Med 44:421–429
4. Gibson MJ, Middlemiss JH (1971) Fibrous dysplasia of bone. Br J Radiol 44:1–13
5. Greco MA, Steiner GC (1986) Ultrastructure of fibrous dysplasia of bone. A study of its fibrous, osseous, and cartilaginous components. Ultrastruct Pathol 10:55–66
6. Harris WH, Dudley HR, Barry RL (1962) The natural history of fibrous dysplasia: an orthopaedic, pathological and roentgenographic study. J Bone Joint Surg Am 44:207–233
7. Henry A (1969) Monostotic fibrous dysplasia. J Bone Joint Surg Br 51:300–306
8. Hu SS, Healey JH, Huvos AG (1990) Fibrous dysplasia of the second cervical vertebra. A case report. J Bone Joint Surg Am 72:781–783
9. Huvos AG, Higinbotham NL, Miller TR (1972) Bone sarcomas arising in fibrous dysplasia. J Bone Joint Surg Am 54: 1047–1056

10. Kahn A III, Rosenberg PS (1988) Monostotic fibrous dysplasia of the lumbar spine. Spine 13:592–593
11. Ledoux-Lebard G, Soulquin C (1953) Les localisations vertebrales de la dysplasie fibreuse des os ou malodie de Jaffe-Lichtenstein. Presse Med 61:272–273
12. Lichtenstein L (1938) Polyostotic fibrous dysplasia. Arch Surg 36:874–898
13. Lichtenstein L, Jaffe HL (1942) Fibrous dysplasia of bone: a condition affecting one, several or many bones, the graver cases of which may present abnormal pigmentation of skin, hyperthyroidism or still other extraskeletal abnormalities. Arch Pathol 33:777–816
14. Nabarro MN, Giblin PE (1994) Monostotic fibrous dysplasia of the thoracic spine. Spine 19:463–465
15. Nigrisoli M (1987) Monostotic fibrous dysplasia of the spine: case report. Ital J Orthop Traumatol 13:273–278
16. Ohki I (1990) Monostotic fibrous dysplasia in the spine. J West Pacif Orthop Assoc 27:107–110
17. Penrod BJ, Haramati N, Frager D, Dorfman HD (1996) A 40-year-old woman with back pain. Clin Imag 20:143–146
18. Przybylski GJ, Pollack IF, Ward WT (1996) Monostotic fibrous dysplasia of the thoracic spine. A case report. Spine 21:860–865
19. Reed RJ (1963) Fibrous dysplasia of bone: a review of 25 cases. Arch Pathol 75:480–495
20. Resnik CS, Lininger JR (1984) Monostotic fibrous dysplasia of the cervical spine: case report. Radiology 151:49–50
21. Ridell DM (1964) Malignant changes in fibrous dysplasia: report of a case. J Bone Joint Surg Br 46:251–155
22. Rosenblum B, Overby C, Levine M, Handler M, Sprecher S (1987) Monostotic fibrous dysplasia of the thoracic spine. Spine 12:939–942
23. Rosendahl-Jensen SV (1956) Fibrous dysplasia of the vertebral column. Acta Chir Scand 111:490–494
24. Schajowicz F (1994) Tumorlike lesions: 6. Fibrous dysplasia and osteofibrous dysplasia. In: Schajowicz F (ed) Tumors and tumorlike lesions of bone. Pathology, radiology and treatment, 2nd edn. Springer, Heidelberg Berlin New York, pp 567–581
25. Schlumberger HG (1946) Fibrous dysplasia of single bones (monostotic fibrous dysplasia). Milit Surg 99:504–527
26. Singer J, Sundaram M, Merenda G, Joyce PF (1991) Fibrous dysplasia of thoracic vertebra arising de novo: cheirurgogenic in origin? Orthopedics 14:355–358
27. Stephenson RB, London MD, Hankin FM, Kaufer H (1987) Fibrous dysplasia. An analysis of options for treatment. J Bone Joint Surg Am 69:400–409
28. Taconis WK (1988) Osteosarcoma in fibrous dysplasia. Skeletal Radiol 17:163–170
29. Troop JK, Herring JA (1988) Monostotic fibrous dysplasia of the lumbar spine: case report and review of the literature. J Pediatr Orthop 8:599–601
30. Wright JF, Stoker DJ (1988) Fibrous dysplasia of the spine. Clin Radiol 39:523–527
31. Yabut SM Jr, Kenan S, Sissons HA, Lewis MM (1988) Malignant transformation of fibrous dysplasia. A case report and review of the literature. Clin Orthop 228:281–289