JOURNAL OF BONE AND MINERAL RESEARCH
Volume 21, Supplement 2, 2006
Online reference number: doi: 10.1359/JBMR.06S219
© 2006 American Society for Bone and Mineral Research

Spectrum and Natural History of Fibrous Dysplasia of Bone

Michael T Collins

INTRODUCTION

THIS PAPER WILL present the major clinical findings in the study of fibrous dysplasia of bone (FD) that have occurred in the 10 years since the last meeting on Paget's disease of bone and FD, which took place at the NIH in 1996. Accompanying monographs will address the molecular and cellular underpinnings that lead to FD (Weinstein and Bianco, respectively), the radiographic findings (Sundarm), the surgical (Stanton), and medical treatment of children (Glorieux) and adults (Chaprulat). The clinical problems and natural history of the disease vary according to the anatomical locations at which the disease occurs. Disease in the craniofacial region tends to overgrow causing disfigurement and has the potential to compress vital structures, such as the optic nerve.[1] In the long bones, FD is often associated with pain, bowing, and fractures.[2] Advancement in our understanding of FD has been impeded by the combination of low prevalence, broad and varied clinical spectrum, and the fact that FD is commonly accompanied by one or more hyperfunctioning endocrinopathies, each of which has its own distinct impact on the underlying skeletal disorder. An example of the complexity of studying and understanding FD is shown by the two patients shown in Fig. 1.

Data from ongoing studies in a relatively large cohort of patients with FD and McCune-Albright Syndrome (MAS) conducted at the NIH over the last 25 years have supplied significant new information to help us understand FD. One hundred four patients (57% females, 43% males) have been seen at the NIH over the last 25 years as subjects in various studies of FD and/or MAS. The average length of observation was 6 years (range, 1–25 years), for >650 patient-years of follow-up. Four percent had monostotic FD, 15% were polyostotic, and 81% had MAS (as defined broadly by FD with either café-au-lait skin pigmentation and/or one of the associated hyperfunctioning endocrinopathies). All patients underwent a detailed review of outside records, clinical examination, biochemical testing, and radiographic imaging. These data have helped define the spectrum of the disease, elucidate the distinct effect of specific hyperfunctioning endocrinopathies on the skeletal disease, give a sense of the natural history of the disease, point to areas where medical intervention is needed, and highlight areas in need of further study.

The authors state that they have no conflicts of interest.

FINDINGS

Quantification of skeletal disease burden

One of the challenges in studying a somatic disease such as FD, which has a broad and varied spectrum, is the lack of a method by which to quantify the amount of disease a patient has (the skeletal disease burden). The ability to do this is important for determining the extent of an individual patient's disease within the spectrum of severity, the association and/or correlation between FD skeletal disease burden and various potential disease modifiers and outcomes, and for the ability to compare patients between studies. To address this challenge, we developed and validated a simple scoring tool for the quantification of the skeletal disease burden.[3] Briefly, using nuclear medicine bone scans, the skeleton is divided into 11 segments, and the amount of the affected skeleton in each section was estimated. The midpoint of that estimate was multiplied by the percent of the skeleton that that segment represents, and the 11 numbers were tallied to give the skeletal disease burden score. The scale is from 0 (no disease) to 75 (100% of the skeleton involved). The skeletal disease burden score correlated with the functional outcome of ambulation (assisted versus unassisted). In addition, the score in childhood (at a time while the disease is still evolving) predicts adult ambulation status, with a skeletal disease burden score >30 predicting the need for assisted ambulation in adulthood. Thus, use of this tool allows for functional prognostication. A representative scan and scoring tool are shown in Fig. 2. The tool is simple, takes <5 minutes to score, is highly reproducible, and is potentially applicable to other diseases with patchy skeletal involvement, such as Paget's disease of bone. Whereas bone metabolism markers, such as alkaline phosphatase, may be used in a similar fashion, these are less reliable because they change in response to treatment (bisphosphonates) or with age (age-dependent decline).

Health-related quality of life

One of the most important measures in clinical medicine is the affect of a disease and/or its treatment on health-related quality of life (HRQL). It is arguably the most important measure to a patient or parent. To determine the effect of FD on HRQL, we studied a group of children and adults with FD.[4] Children were administered the Child Health Questionnaire Parent Form 50 (CHQ-PF50), and adults the Short-Form Health Survey volume 2 (SF-36), which are standardized and validated measures of HRQL.

Craniofacial and Skeletal Diseases Branch, National Institute of Dental and Craniofacial Research, National Institutes of Health, Department of Health and Human Services, Bethesda, Maryland, USA.

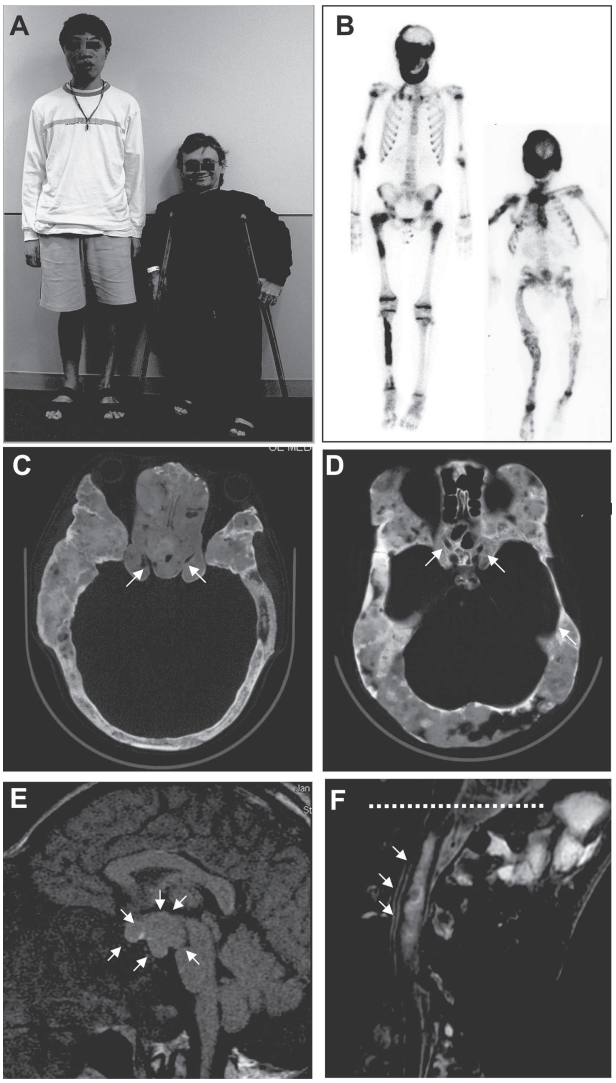

FIG. 1. Disease spectrum and complexity in FD. (A) Two patients with FD and McCune-Albright syndrome. The patient on the left has gigantism/acromegaly caused by GH excess, and the patient on the right has short stature caused by precocious puberty. Both are disabled. The patient on the left is blind, whereas the other patient is crutch- and wheelchair-dependent for ambulation. The patient on the left also has central hypothyroidism and hypogonadism, and the patient on the right has renal phosphate wasting, hyperthyroidism, and Leydig cell hyperplasia of the testes. (B) The extent and location of FD is shown by the bone scans). The skeletal burden score of the left is 42.4/75 and of the right is 68.1/75. The very high score of the patient on the right is consistent with and explains his renal phosphate wasting. (C and D) Head CTs at the level of the optic nerves (arrowheads). (C) In the GH excess patient on the left, compression of the right optic nerve is shown, and (D) in the patient on the right, the nerve canals are patent and vision normal, despite 100% encasement of many years duration. Head MRIs show the complications of a massive pituitary adenoma (E, arrow heads) and platybasia of the skull base with a resultant Chiari I malformation (dashed line indicates the level of the occipital skull base with brain stem extension below) and syrinx (arrowheads). This very rare finding in a patient with FD is thought to be associated with decades of untreated hypophosphatemia and hyperthyroidism.

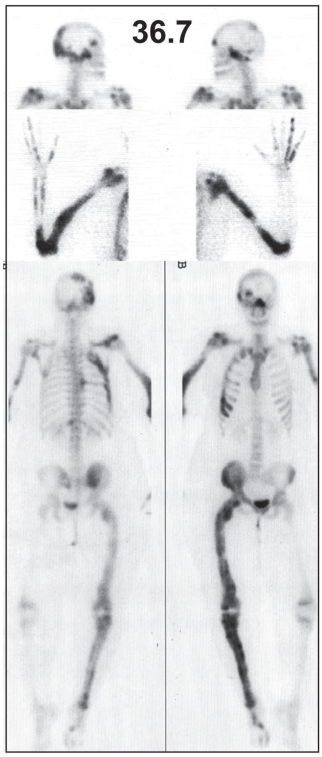

Site	Area (%) 0	0-5	5-25	25-50	>50
Skull			X		
Right Upper Extremity					X
Left Upper Extremity					X
Right Lower Extremity					X
Left Lower Extremity	X				
Spine		X			
Right Ribs				X	
Left Ribs	X				
Sternum			X		
Right Pelvis					X
Left Pelvis	X				

FIG. 2. Skeletal disease burden scoring tool. A representative ^{99}Tc-MDP bone scan of a patient who is cane ambulator and the tool used to quantify the skeletal disease burden are shown. The percent involvement in each segment is estimated, and using the following calculation, the score is derived: $(0.1837 \times 15) + 0.1908[(75 + 75)/2] + 0.0441(75 + 0)/2 + 0.0833(2.5) + 0.0747(37.5 + 0)/2 + 0.4206(15 + 75)/2 + 0.003(0) = 36.7$ (a Microsoft Excel file with the calculator is available from the author on request).

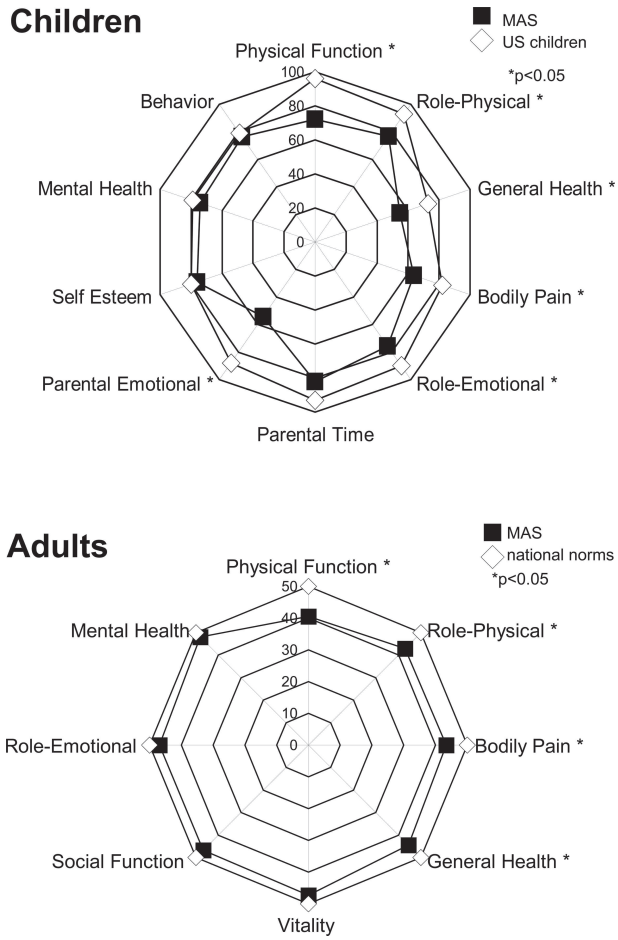

FIG. 3. HRQL in patients with FD. Radar graphs of the results of HRQL testing in children, (A) CHQ-PF50 and (B) adult SF-36 are shown. Patients were compared with national norms, and statistically significant differences ($p < 0.05$) are denoted by *. In both groups, there was an effect of FD on the physical domains that was positively correlated with the skeletal disease burden score: greater burden, lower scores. In general, in children and adults, the psycho-social domains were unaffected. The domain most profoundly affected was the Parental-Emotional domain of the parents of children with FD.

We found that, in children with FD, there was a statistically significant decrease in the domains of Physical Function, Role-Physical, General Health, Bodily Pain, Role-Emotional, and Parental Emotional (Fig. 3) and that the degree of decrease correlated with the skeletal disease burden score. Interestingly, the most profoundly effected domain was that of Parental Emotional, showing that the emotional burden parents of children with FD bear is significant. Similarly, adults scored significantly lower in the domains of Physical Function, Role-Physical, and General Health (Fig. 3), in a skeletal disease burden–dependent fashion. Importantly, adults scored normally in the domains of Vitality, Social Function, Role-Emotional, and Mental Health, indicating that, despite physical impairment, psycho-social function was unaffected. These data serve as baseline measures for future intervention studies and highlight the importance of addressing the psychological impact on parents. At the same time, they provide hope to parents that there is no long-term impact of the disease on psycho-social functioning.

Optic neuropathy and optic nerve decompression in FD

A longtime vexing and clinically debated area in the study of craniofacial FD is that of the management of FD encasing the optic nerves. The abiding opinion in the surgical literature had been that FD encasing the optic nerves leads to optic neuropathy and blindness.[5] Therefore, it had been argued that, when the optic nerves are encased by FD, even in the absence of symptoms, they should be decompressed prophylactically to prevent the inexorable progression to blindness.[5] This, however, had not been our experience.[5] In our population of patients with relatively severe disease, vision loss occurred in only 5% of the patients, whereas in 86% of the patients in whom nerves were 100% encased with FD, vision was normal.[6] Furthermore, the group with vision problems were not older than those without, suggesting there was not an age-dependent progression to vision loss. Given the relative rarity of blindness in FD and the absence of any evidence of age-related progressive optic neuropathy, optic nerve decompression in the absence of symptoms of optic neuropathy is clearly contraindicated.

Growth hormone excess on craniofacial FD

Even though vision and clinically significant hearing loss are uncommon in FD, it is important to know what clinical

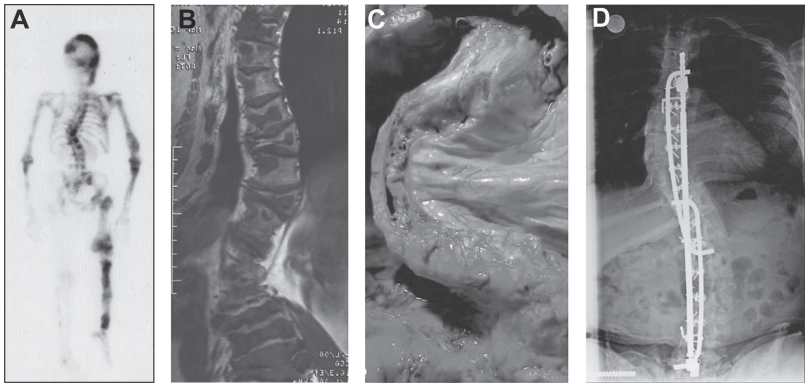

FIG. 4. (A) FD of the spine and scoliosis. FD in the spine, as shown by a ^{99}Tc-MDP bone scan, is a common finding in patients with FD (63% of the patients in the NIH series). (B) Involvement can be striking, as shown by this MRI image. Surprisingly, as was the case for the patient in B, there are usually no neurological sequelae. When FD is present in the spine, it is often associated with scoliosis (40% with spinal FD have scoliosis). (C) Clinically, this is significant because it may continue to progress into adulthood, and in the most severe cases, may lead to death. (D) Importantly, fixation is usually effective and lasting.

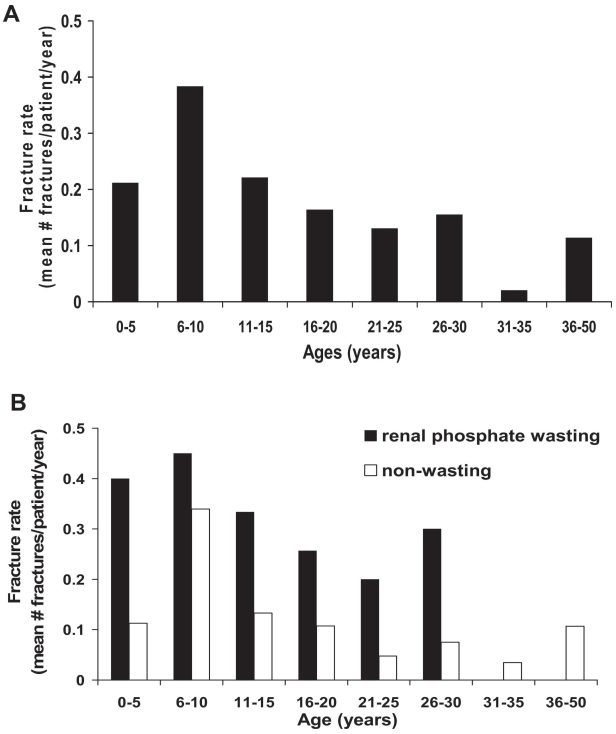

FIG. 5. Fractures in FD. (A) The fracture rate across the lifespan in patients with FD. The fracture rate peaks in the 6- to 10-year-old age group, but continues at a significant rate into adulthood. The only endocrine/metabolic aspect of FD that was associated with an increased fracture rate in FD was renal phosphate wasting. (B) In all age groups, the patients with renal phosphate wasting had fracture rates approximately twice that of those without.

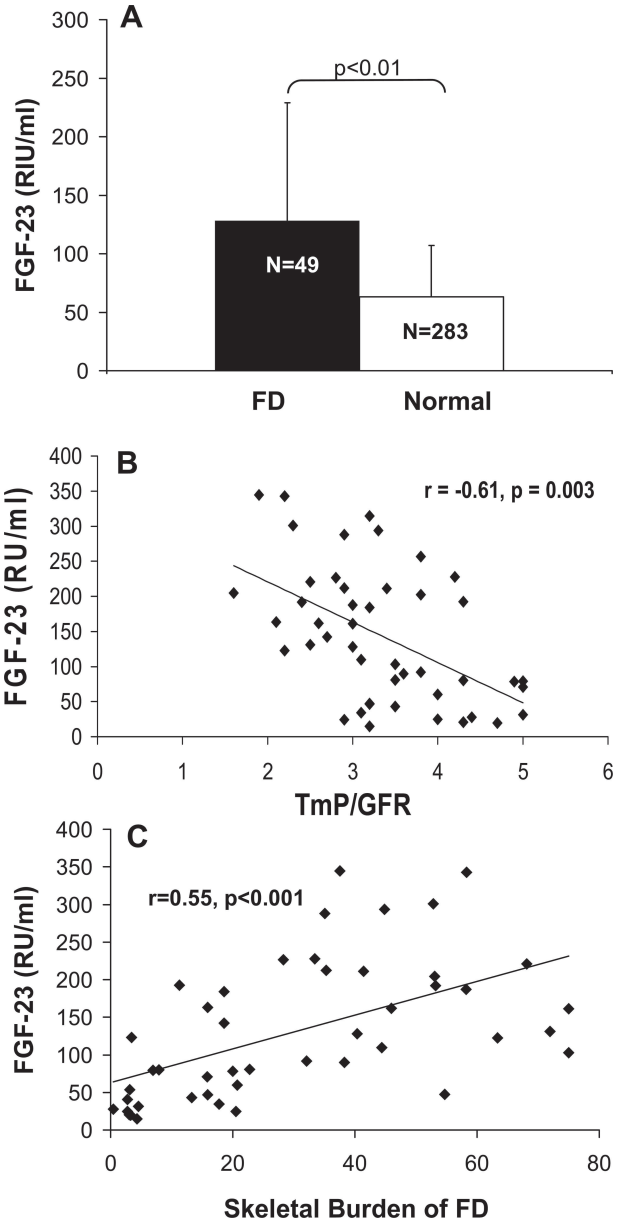

FIG. 6. FGF-23 in FD. (A) Patients with FD were found to have higher serum FGF-22 levels than controls. (B) Higher serum levels of FGF-23 are associated with greater renal phosphate wasting, as shown by the inverse correlation between FGF-23 and TmP/GFR. (C) Evidence that the FD tissue may be the source of the elevated FGF-23 is shown by the fact that serum FGF-23 levels correlate with the skeletal disease burden.

aspects of the disease are associated with, and perhaps causative, of craniofacial morbidity. An analysis of the endocrinologic and metabolic problems found in association with craniofacial FD morbidity, including vision and hearing loss and macrocephaly, identified growth hormone (GH) excess as the single aspect of MAS associated with an increase in morbidity in craniofacial FD.[6] GH excess was associated with a statistically significant increase in the relative risk for blindness, severe hearing loss, and the need for surgery.[6] In addition, GH excess leads to macrocephaly,[7] with a statistically significant linear correlation between the degree of GH excess and head circumference.[8] One of the important clinical implications for this is the need for early diagnosis and treatment of GH excess in children with craniofacial FD. Children with GH excess are usually asymptomatic and without obvious signs or symptoms of GH excess. The assumption is that control of GH excess will prevent long-term craniofacial morbidity. Whether early treatment will prevent late sequelae remains to be seen, but at this time, treatment would seem to be a reasonable approach, because medical treatment is usually effective in normalizing serum IGF-1.[8,9]

Spinal involvement with FD and scoliosis

Involvement of the spine with FD had been thought to be a rare occurrence, usually the subject of case reports or small series.[10] However, we found that FD is commonly seen in the spine (63% of the patients), and that when present, it is often associated with scoliosis (40% of the patients with spinal FD; Fig. 4).[10] Whereas the prevalence in our group may be high because of a bias toward more severe disease, it is clear that spinal FD is not rare. The importance of this finding is that untreated scoliosis in FD can lead to pulmonary compromise and death. It seems that in scoliosis associated with FD, unlike idiopathic FD, curve progression after growth plate fusion is common. The

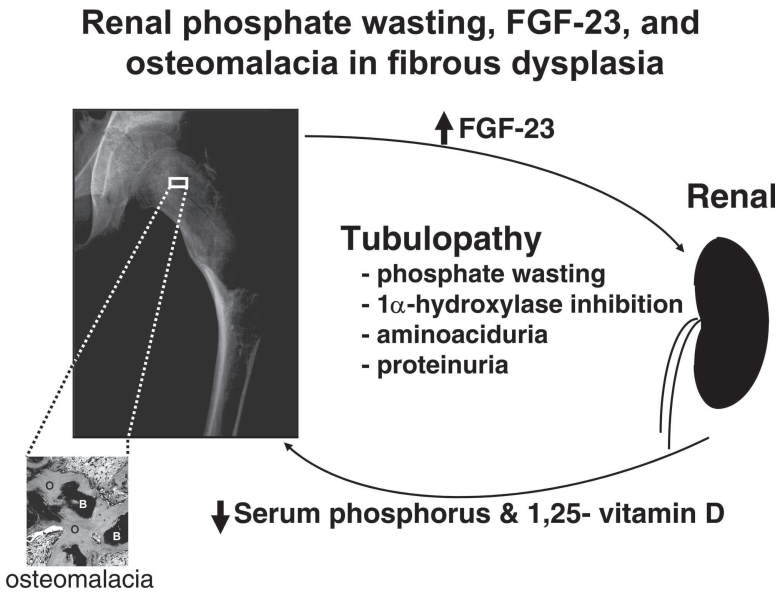

FIG. 7. Model of the interplay between FD, renal phosphate wasting, and FGF-23. FD tissue overproduces FGF-23, which has the effect at the kidney of inducing a proximal tubulopathy including phosphaturia. The resultant low serum phosphors and 1,25 vitamin D has the effect of contributing to the lesional osteomalacia seen in FD (figure concept, PG Robey).

bright spot in this finding is that fixation seems to be quite effective for long-term stabilization. In our series, stability has been maintained up to 26 years after fixation. However, work remains to be done to determine what factors are associated with curve progression, to see whether bracing will prevent progression and to define the criteria for the interval of follow-up and the Cobb angles at which bracing and surgery should be instituted.

Fractures in FD

One of the most common and problematic clinical issues in FD is fractures. Important questions are as follows: when do fractures occur, does the propensity to fractures diminish over time, and what aspects of the disease contribute to the tendency to fracture? We have found that, whereas the peak rate of fractures was in the 6- to 10-year-old age group (0.4 fractures/year), there was a sustained fracture rate throughout adulthood (Fig. 5A).[11] We also found that the fracture rate in almost all age groups is at least twice as high in patients who have the commonly associated metabolic problem of renal phosphate wasting (Fig. 5B).[11] Whereas part of the reason fracture rates are higher in the group with renal phosphate wasting is that these patients also tend to have more disease, there probably is also a contribution of frank or relative hypophosphatemia to increased bone fragility. Evidence for this is the fact that patients with renal phosphate wasting tend to have more osteoid in FD tissue.[12,13] Whereas treatment of hypophosphatemia with oral phosphorus and calcitriol is usually initiated in these patients, it is not a forgone conclusion that this treatment will be beneficial. Further studies are needed to clarify this.

Renal phosphate wasting and hypophosphatemia in FD

It was originally felt that the etiology of renal phosphate wasting in FD was the presence of the *Gsα* mutation in the renal proximal tubule cells.[14] However, the findings of a detailed clinical evaluation of a relatively large group of patients with FD were more consistent with the presence of a circulating, phosphate-regulating factor (phosphatonin) than that of a PTH-like effect of a somatic mutation in the renal proximal tubule.[15] It was further shown that serum levels of the potent phosphaturic agent, fibroblast growth factor-23 (FGF-23), are elevated in patients with FD (Fig. 6A),[16,17] that the degree of phosphate wasting (as measured by tubular maximum of phosphorus per glomerular filtration rate [TmP/GFR]) correlates with the degree of elevation of FGF-23 (Fig. 6B), and that the serum levels of FGF-23 correlate with the skeletal disease burden of FD (Fig. 6C). These data suggest that the diseased bone in FD may be the source of the elevated levels of FGF-23, which was confirmed by the demonstration of high levels of FGF-23 mRNA in FD tissue.[16] This important finding led to the observation that normal bone is also positive for FGF-23 mRNA,[16] a finding that has been confirmed by others,[18,19] and that bone may be the physiologic source of circulating FGF-23. These findings have led to the development of a model in which FD bone is the source of elevated levels of FGF-23, FGF-23 in turn acts at the kidney to lower serum phosphorus and 1,25-dihydroxyvitamin D, and that low serum phosphorus at least contributes to worsening of the lesional osteomalacia that is observed in FD (Fig. 7).

CONCLUSIONS

In the last 10 years, significant progress has been made in our understanding of FD. The development of a tool to quantify skeletal disease burden has assisted in our ability to compare patients, measure HRQL, and predict functional outcomes. We have learned that FD encasing the optic nerve is a stable condition and that prophylactic optic nerve decompression is contraindicated. It is important to screen for and treat GH excess in childhood, because in its

presence and if untreated, it is associated with greater craniofacial morbidity, including blindness. Similarly, it is important to screen for, monitor, and treat scoliosis in association with FD because it is common, treatable, and if untreated can lead to death. We have learned that the fracture rate is highest between the ages of 6–10 years, that the rate decreases thereafter but persists well into adulthood, and that renal phosphate wasting and hypophosphatemia are associated with higher fracture rates. Finally, the finding of elevated levels of serum FGF-23, of FD tissue origin, has explained the phosphate metabolism defects in FD and contributed to the exciting new area of FGF-23–related mineral metabolism.

ACKNOWLEDGMENTS

FD Investigators: Sunday Akintoye, Paolo Bianco, Susan Booher, Alan Boyde, Jaime Brahim, Beth Brillante, John Butman, Usha Chauhdry, Caroline Chebli, Clara Chen, Natasha Cherman, Alesandro Corsi, Carolee Cutler, Craig R Dufresne, Neal S Fedarko, Penelope Feuillan, Larry Fisher, Edmund FitzGibbon, Anurag Gupta, Janet Jones, Jeffrey Kim, Marilyn H Kelly, Harvey Kushner, Sergei A Kuznetsov, Janice S Lee, Arabella I Leet, Mahesh Mankani, Scott Paul, Mara Riminucci, Pamela G Robey, Shlomo Wientroub, and Navid Ziran. This research was funded by the Intramural Program of the NIH, NIDCR.

REFERENCES

1. Riminucci M, Collins MT, Jane JA, Lin KY 2002 Craniofacial fibrous dysplasia. In: Lin KY, Ogle RC, Jane JA (eds.) Craniofacial Surgery. W.B. Saunders, Philadelphia, PA, USA, pp. 366–381.
2. Collins MT, Bianco P 2003 Fibrous dysplasia. In: Favus MJ (ed.) Primer on the Metabolic Bone Diseases and Disorders of Mineral Metabolism, 5th ed. American Society for Bone and Mineral Research, Washington, DC, USA, pp. 466–470.
3. Collins MT, Kushner H, Reynolds JC, Chebli C, Kelly MH, Gupta A, Brillante B, Leet AI, Riminucci M, Robey PG, Bianco P, Wientroub S, Chen CC 2005 An instrument to measure skeletal burden and predict functional outcome in fibrous dysplasia of bone. J Bone Miner Res **20:**219–226.
4. Kelly MH, Brillante B, Kushner H, Gehron Robey P, Collins MT 2005 Physical function is impaired but quality of life preserved in patients with fibrous dysplasia of bone. Bone **37:**388–394.
5. Lee JS, FitzGibbon E, Butman JA, Dufresne CR, Kushner H, Wientroub S, Robey PG, Collins MT 2002 Normal vision despite narrowing of the optic canal in fibrous dysplasia. N Engl J Med **347:**1670–1676.
6. Cutler CM, Dufresne CR, Collins MT 2005 Characterization of the craniofacial effects of fibrous dysplasia and McCune-Albright syndrome. Proc of the Xith Inter Conbress of Inter Soc of Craniofacial Surg (in press).
7. Uwaifo GI, Robey PG, Akintoye SO, Collins MT 2001 Clinical picture: Fuel on the fire. Lancet **357:**2011.
8. Akintoye SO, Kelly MH, Brillante B, Cherman N, Turner S, Butman JA, Robey P, Collins MT 2006 Pegvisomant for the treatment of gsp-mediated growth hormone excess in patients with McCune-Albright syndrome. J Clin Endocrinol Metab **91:**2960–2966.
9. Akintoye SO, Chebli C, Booher S, Feuillan P, Kushner H, Leroith D, Cherman N, Bianco P, Wientroub S, Robey PG, Collins MT 2002 Characterization of gsp-mediated growth hormone excess in the context of McCune-Albright syndrome. J Clin Endocrinol Metab **87:**5104–5112.
10. Leet AI, Magur E, Lee JS, Wientroub S, Robey PG, Collins MT 2004 Fibrous dysplasia in the spine: Prevalence of lesions and association with scoliosis. J Bone Joint Surg Am **86:**531–537.
11. Leet AI, Chebli C, Kushner H, Chen CC, Kelly MH, Brillante BA, Robey PG, Bianco P, Wientroub S, Collins MT 2004 Fracture Incidence in Polyostotic Fibrous Dysplasia and the McCune-Albright Syndrome. J Bone Miner Res **19:**571–577.
12. Terpstra L, Rauch F, Plotkin H, Travers R, Glorieux FH 2002 Bone mineralization in polyostotic fibrous dysplasia: Histomorphometric analysis. J Bone Miner Res **17:**1949–1953.
13. Corsi A, Collins MT, Riminucci M, Howell PG, Boyde A, Robey PG, Bianco P 2003 Osteomalacic and hyperparathyroid changes in fibrous dysplasia of bone: Core biopsy studies and clinical correlations. J Bone Miner Res **18:**1235–1246.
14. Zung A, Chalew SA, Schwindinger WF, Levine MA, Phillip M, Jara A, Counts DR, Kowarski AA 1995 Urinary cyclic adenosine 3′,5′-monophosphate response in McCune- Albright syndrome: Clinical evidence for altered renal adenylate cyclase activity. J Clin Endocrinol Metab **80:**3576–3581.
15. Collins MT, Chebli C, Jones J, Kushner H, Consugar M, Rinaldo P, Wientroub S, Bianco P, Robey PG 2001 Renal phosphate wasting in fibrous dysplasia of bone is part of a generalized renal tubular dysfunction similar to that seen in tumor-induced osteomalacia. J Bone Miner Res **16:**806–813.
16. Riminucci M, Collins MT, Fedarko NS, Cherman N, Corsi A, White KE, Waguespack S, Gupta A, Hannon T, Econs MJ, Bianco P, Gehron Robey P 2003 FGF-23 in fibrous dysplasia of bone and its relationship to renal phosphate wasting. J Clin Invest **112:**683–692.
17. Yamamoto T, Imanishi Y, Kinoshita E, Nakagomi Y, Shimizu N, Miyauchi A, Satomura K, Koshiyama H, Inaba M, Nishizawa Y, Juppner H, Ozono K 2005 The role of fibroblast growth factor 23 for hypophosphatemia and abnormal regulation of vitamin D metabolism in patients with McCune-Albright syndrome. J Bone Miner Metab **23:**231–237.
18. Sitara D, Razzaque MS, Hesse M, Yoganathan S, Taguchi T, Erben RG, H JA-P, Lanske B 2004 Homozygous ablation of fibroblast growth factor-23 results in hyperphosphatemia and impaired skeletogenesis, and reverses hypophosphatemia in Phex-deficient mice. Matrix Biol **23:**421–432.
19. Mirams M, Robinson BG, Mason RS, Nelson AE 2004 Bone as a source of FGF23: Regulation by phosphate? Bone **35:**1192–1199.

Address reprint requests to:
Michael T Collins, MD
Skeletal Clinical Studies Unit
CSDB, NIDCR, NIH Building 30, Room 228
MSC 4320
Bethesda, MD 20892-4320, USA
E-mail: mc247k@nih.gov

Received in original form March 1, 2006; revised form May 18, 2006; accepted October 11, 2006.