JOURNAL OF BONE AND MINERAL RESEARCH
Volume 21, Number 12, 2006
Published online on August 28, 2006; doi: 10.1359/JBMR.060818
© 2006 American Society for Bone and Mineral Research

Clinical Vignette

Monostotic Fibrous Dysplasia of the Proximal Femur and Liposclerosing Myxofibrous Tumor: Which One Is Which?

Alessandro Corsi,[1] Fernando De Maio,[2] Ernesto Ippolito,[2] Natasha Cherman,[3] Pamela Gehron Robey,[3] Mara Riminucci,[4,5] and Paolo Bianco[1,5]

ABSTRACT: Clinical, histological, and genetic studies of two cases of isolated fibro-osseous lesions of the femur in adults show the overlap between monostotic fibrous dysplasia (MFD) of the proximal femur and the so-called liposclerosing myxofibrous tumor. The two cases highlight how the incomplete understanding of the natural history of MFD may result in diagnostic pitfalls or incorrect classification of individual lesions.
J Bone Miner Res 2006;21:1955–1958. Published online on August 28, 2006; doi: 10.1359/JBMR.060818

Key words: fibrous dysplasia, monostotic, guanine nucleotide–binding protein, alpha stimulating activity polypeptide, mutation, liposclerosing myxofibrous tumor

CASE 1

A 33-year-old woman was diagnosed elsewhere with monostotic fibrous dysplasia (FD), based on radiographic and histological evaluation. The patient complained of pain in the left hip. Bilateral ovarian cysts were noted in her past medical history. Radiographic examination showed a ground-glass lesion within the left femur neck, consistent with FD. A bone scan showed increased uptake exclusively at this site. Physical examination revealed a "café-au-lait spot" on the left thigh. Review of the histological material confirmed the diagnosis of FD. Curettage was performed, and femur neck stabilization was obtained with a dynamic hip screw. The patient was well 2 years after surgery. Histological studies of the curetted material again revealed a picture regarded as diagnostic of FD (Figs. 1A–1C). Fresh surgical material, cells isolated in culture from the surgical material, paraffin blocks of the original bone biopsy, and a punch biopsy of the cafè-au-lait spot were used for extraction of genomic DNA and mutation analysis. Direct sequencing of the PCR amplification products (Fig. 1D) failed to disclose activating guanine nucleotide–binding protein, alpha stimulating activity polypeptide (*GNAS*) mutations at codon 201, which typically associate with, and cause, FD lesions.[1] Given the somatic mosaic nature of FD lesions,[2] mutated cells can escape detection by conventional PCR sequencing if present in low numbers. Therefore, mutation analysis was repeated using the more sensitive peptide nucleic acid (PNA) clamping[1] and PCR-restriction fragment length polymorphism (PCR-RFLP)[3] techniques. Again, no mutation could be shown (Figs. 1E–1F). No mutations of codon 227 of the *GNAS* gene[4] could be shown either (data not shown). The absence of demonstrable *GNAS* mutations prompted a retrospective analysis of all available clinical material. A review of radiographs performed (for unrelated reasons) 6 years before the onset of symptoms showed the absence of any lesion in the left proximal femur (Figs. 1G–1H) and implied the development of an FD-like lesion de novo in the adult life. Being at odds with the notion that FD lesions develop during bone growth,[2] this finding further challenged the diagnosis of FD. Careful consideration of the differential diagnosis focused on lesions that would mimic FD so closely as to be indistinguishable based on histology. Liposclerosing myxofibrous tumor (LSMFT[5–11]) emerged as the only plausible candidate. A benign fibro-osseous bone lesion regarded as a distinct clinical-pathological entity, and first described in 1986,[5] LSMFT usually occurs in the proximal femur of adults. The admixture of myxofibrous tissue and abnormal bone trabeculae noted as FD-like[5–11] characterize LSMFT histologically. Most of the elemental features that purportedly define the LSMFT-specific histological pattern (myxoid areas, woven bone, active osteoclastic resorption, lipid-laden macrophages, adipocyte clusters, spheritic mineral clusters within the fibrous tissue) can all be observed in FD as well,[12,13] and were all observed in our case. Regardless of the uncertain definition of the nature of LSFMT, we reluctantly entertained the diagnosis of LSMFT as consistent with histological findings and with the absence of *GNAS* mutations and more consistent with clinical features than the diagnosis of FD.

The authors state that they have no conflicts of interest.

[1]Dipartimento di Medicina Sperimentale e Patologia, Università "La Sapienza," Rome, Italy; [2]Dipartimento di Chirurgia Ortopedica, Università di Tor Vergata, Rome, Italy; [3]Craniofacial and Skeletal Diseases Branch, National Institute of Dental and Craniofacial Research, National Institutes of Health, Bethesda, Maryland, USA; [4]Dipartimento di Medicina Sperimentale, Università dell'Aquila, L'Aquila, Italy; [5]Parco Scientifico Biomedico San Raffaele, Rome, Italy.

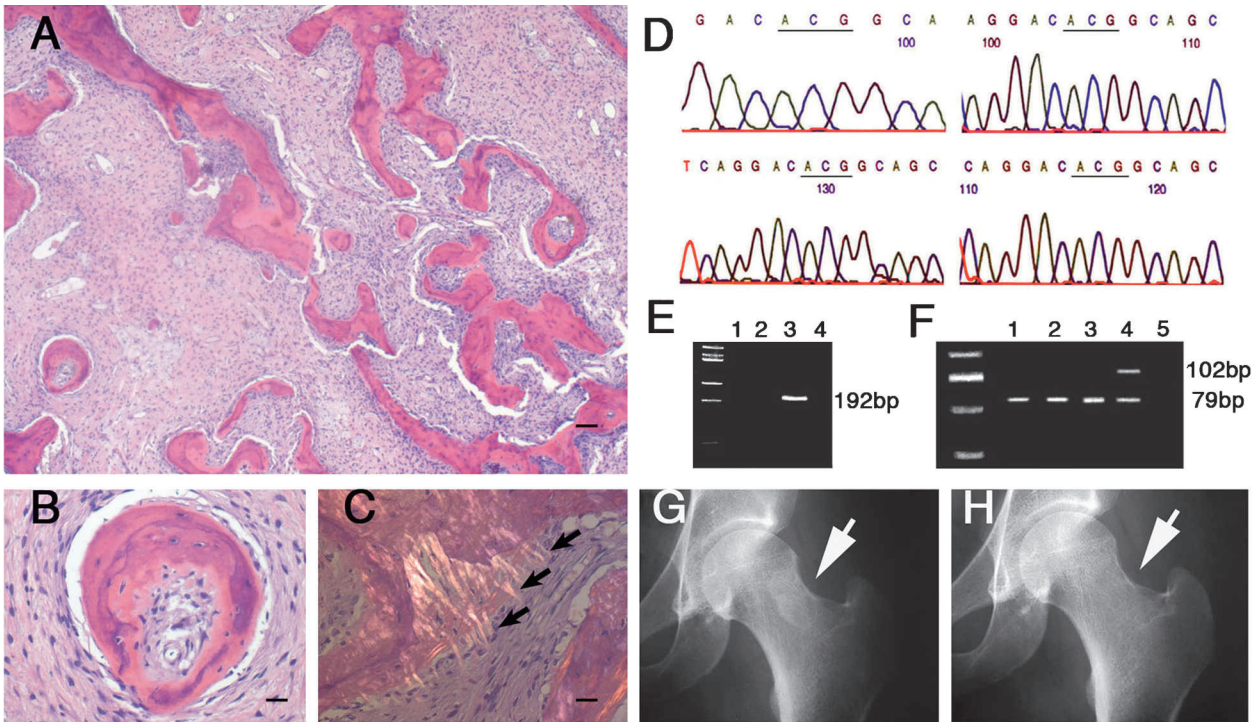

FIG. 1. Case 1. (A–C) Overview (A) and details of the histology of the lesion, showing diagnostic features of FD, including (A and B) admixture of fibrous and bone tissues, (A and B) "Chinese writing" pattern of bone trabeculae, (C) woven bone, and (C) Sharpey fibers (arrows; scale bar: A, 300 μm; B and C, 100 μm). (D) Absence of activating *GNAS* mutations as shown by PCR-sequencing of genomic DNA from biopsy (top left), curettage material (top right), cells grown in culture from curettage material (bottom left), and biopsy of the café-au-lait spot (fresh tissue; bottom right). Normal sequence of codon 201 (shown in reverse and underlined) is shown in all samples. (E) Agarose gel electrophoresis of the PNA-clamped PCR product. Only the mutated allele is amplified. Lane 1, patient's DNA; lane 2, age- and sex-matched negative control (normal donor); lane 3, age-and sex-matched positive control (mutation-positive patient with FD); lane 4, no template, primers only. (F) PCR-RFLP analysis of *GNAS* mutations at codon R201. *Eag*I digestion of the normal allele results in 79- and 23-bp fragments (23-bp fragment not shown). The *Eag*I-undigested mutated allele results in a 102-bp fragment. Lane 1, patient's DNA from biopsy; lane 2, patient's DNA from curettage material; lane 3, age- and sex-matched normal control; lane 4, age- and sex-matched positive control (mutation-positive patient with FD); lane 5, no template, primers only. (G) Radiographic appearance of the lesion (arrow) at admission. (H) Absence of any lesion at the corresponding site in a radiograph taken 6 years before onset of symptoms.

CASE 2

The patient, an ex-professional dancer, was a 54-year-old woman. A lesion of the left proximal femur was incidentally detected during an X-ray study of the gastrointestinal tract. Further ad hoc X-ray studies revealed a lucent lesion with scattered densities and a sclerotic rind, located in the intertrochanteric region of the left femur, consistent with either LSMFT or FD (Fig. 2A). The lesion was treated with curettage and bone grafting, and the femoral neck was stabilized with a dynamic hip screw. The patient was well 1 year after surgery. Histological examination revealed a fibro-osseous lesion with a predominant fibrous component and rounded trabeculae of woven bone, more sparse and less irregular than in typical FD (Fig. 2B). The fibrous tissue, more dense than the one usually seen in FD, was interspersed with myxoid areas (Fig. 2C). In addition, large areas of ischemic-type mineralization of the fibrous tissue, which typically are not seen in FD, and admittedly represent a hallmark of LSMFT[5–11] were obvious (Fig. 2D). Perivascular collections of lipid-laden macrophages (xanthoma cells) were prominent. Overall, the histology was consistent with the diagnosis of LSFMT. However, activating *GNAS* mutations were sought on tissue dissected from the paraffin block. Direct sequencing of the PCR amplification product (Fig. 2E) and *Nla*III restriction analysis (Fig. 2F) unequivocally showed an R201H mutation, which led us to conclude that the lesion was a histologically nontypical, genetically proven example of FD.

DISCUSSION

In case 1, the histological picture was considered as diagnostic of FD by four experienced pathologists at three different institutions, and the radiographic picture was fully consistent with FD. The diagnosis of FD was dispelled, however, by the absence of demonstrable *GNAS* mutations, leaving the diagnosis of LSMFT as the sole possible alternative diagnosis. In the presence of a typical clinical, histological, and radiographic picture, the absence of demonstrable mutation, per se, would not suffice to rule out FD.[2] Given the somatic mosaic nature of FD, the frequency of mutated cells may vary significantly in different lesions, also as a function of age.[2] Thus, it is not incon-

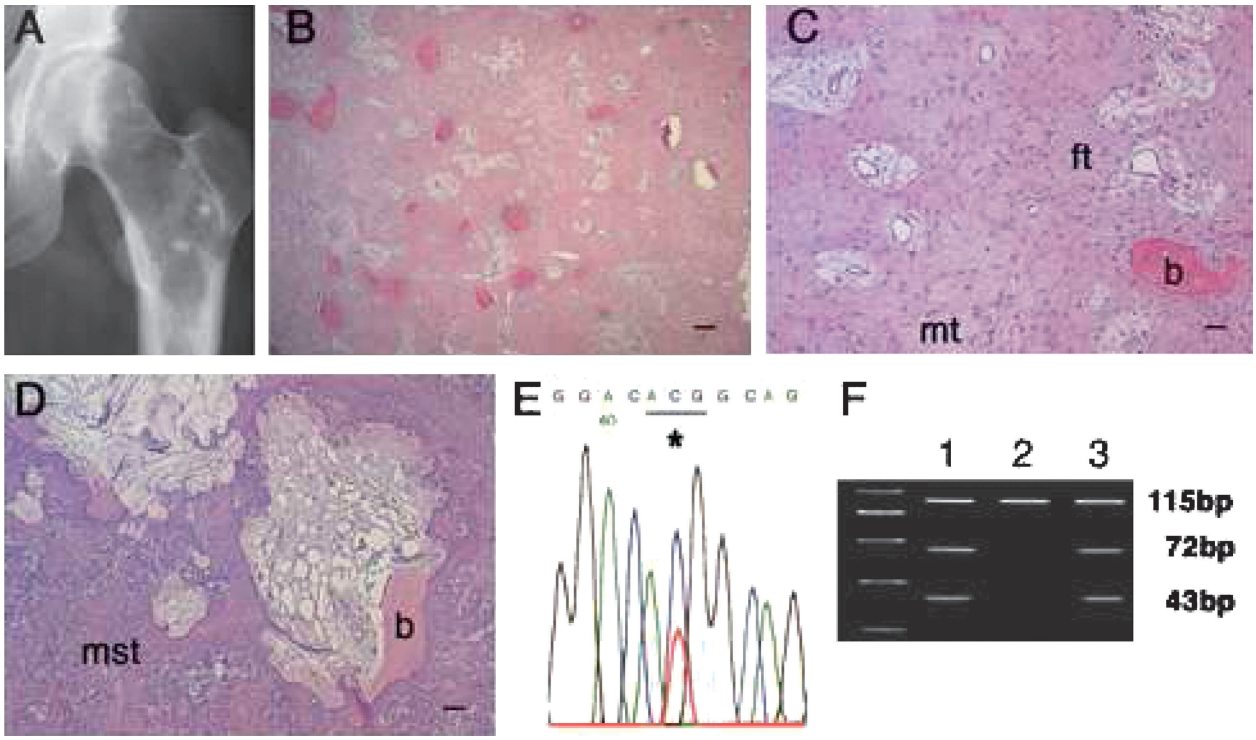

FIG. 2. Case 2. (A) Radiograph showing the lytic intertrochanteric lesion, with scattered densities and perilesional sclerosis. (B–D) Histology showing a fibro-osseous pattern, nontypical for FD (A), and including large areas of myxoid (B, mt) and dense fibrous tissue (B, ft), rounded trabecular of woven bone (B, b), and extensive areas of soft tissue mineralization (of ischemic type; D; mst, mineralized soft tissue; scale bar: B, 500 μm; C and D, 100 μm). (E) *R201H* mutation of the *GNAS* gene (*). Reverse sequence of the PCR product. (F) *Nla*III digestion of the PCR product, showing the *Nla*III restriction site introduced by the R201H mutation. The R201H amplification product fragment (115 bp) is digested into 72- and 43-bp fragments, whereas the normal allele is not digested. Lane 1, patient's DNA from biopsy (paraffin embedded tissue); lane 2, age- and sex-matched negative control; lane 3, age- and sex-matched *R201H* positive control (patient with FD).

ceivable that mutation may remain undetectable, perhaps also as a result of random sampling. However, the mutation was undetectable in our case, even when two highly sensitive methods[1,3] were used. In addition, direct evidence for adult onset of the femoral lesion was available in this case, further challenging the diagnosis of FD. Adult onset of FD lesions has in fact never been documented before, and all cases of FD are thought to represent the clinical expressions of prenatal *GNAS* mutations.[2]

In case 2, conversely, the histological picture was directly suggestive of LSMFT. In particular, the extensive areas of secondary mineralization of the intralesional soft tissue and the prominent perivascular collections of foam cells[5–11] contributed to generate a picture quite departed from typical FD. However, the demonstration of the R201H mutation in the *GNAS* gene led us to conclude that this was true FD. In this case, the lesion was clinically detected in adulthood, but there was no direct evidence for its de novo development in adult life. Before detection, however, the patient had a successful career as a professional dancer, which per se indicates the lack of any significant physical impairment for a lifetime.

The similarity of the overall histological and radiographic picture of LSFMT with that of FD has been repeatedly noted[5–11] and has suggested a hitherto nonclarified relationship between the two entities. Heim-Hall et al.,[10] for example, speculated that the histology of LSMFT might represent the reaction of FD tissue to fatigue stresses, which may alter the histological pattern of FD. For example, stress fractures may lead to local ischemia resulting in extensive intralesional soft tissue mineralization,[10] as observed in case 2. Matsuba et al.[9] showed *GNAS* R201 mutations in two cases of histologically diagnosed LSMFT. Our case 2 may thus be considered as the third case of pathologically diagnosed LSMFT in which an activating *GNAS* mutation is shown, of a total of three in which it was specifically sought. At least a proportion (and possibly all) of the cases that are diagnosed as LSMFT based on radiographic or pathological findings may therefore represent genetically proven FD lesions, in which secondary changes may have significantly altered the histopathological pattern. Advocating LSMFT as a distinct entity based on radiographic and pathologic findings alone[7] would thus not be warranted. If so, histologically typical FD lesions like case 1 would paradoxically be left with no sensible differential diagnosis. One would be forced to conclude that R201 and Q227 *GNAS* mutation-negative, adult-onset, monostotic FD may exist as a variant of FD. Alternatively, one might argue that, based on clinical and genetic considerations, lesions of this kind should not be regarded as FD. If so, the nature and identity of clinically atypical, mutation-negative, FD-like lesions would have to be redefined, but the (*GNAS*

mutation positive) LSMFT would not be a viable option for their alternative classification.

Further study is needed to conclusively clarify whether true FD can arise de novo in adult life, perhaps as a result of somatic mutations occurring in the postnatal life, as opposed to embryonic development. The occurrence of mutation in a postnatal somatic cell, rather than in an embryonic cell, might result in a mutated clone of comparatively limited size and lifespan, conceivably resulting in a low mutation load in the affected tissue.[2] Certain monostotic FD lesions detected in the proximal femur of adults might thus be seen as pathogenetically distinct from the polyostotic FD resulting from embryonic *GNAS* mutations. *GNAS* mutation analysis has only been conducted in a relatively small number of monostotic FD lesions to date.[1,14–16] Therefore, no precise conclusion can be drawn as to how consistently they can be clinically observed in monostotic FD compared with the polyostotic forms and McCune-Albright syndrome. Not inconceivably, an individual case of monostotic FD may turn out to be mutation negative and therefore be misinterpreted as a different entity, such as LSMFT. On the other hand, at least some cases of so-called LSMFT in fact represent genetically proven FD. These two cases show how uncertainties over the natural history of monostotic FD may generate diagnostic pitfalls and an improper classification of bone lesions.

ACKNOWLEDGMENTS

This study was supported in part by grants from Telethon Fondazione Onlus to PB (GGP04263) and DIR, NIDCR of the IRP, and NIH to PGR.

REFERENCES

1. Bianco P, Riminucci M, Majolagbe A, Kuznetsov SA, Collins MT, Mankani MH, Corsi A, Bone HG, Wientroub S, Spiegel AM, Fisher LW, Robey PG 2000 Mutations of the GNAS1 gene, stromal cell dysfunction, and osteomalacic changes in non-McCune-Albright fibrous dysplasia of bone. J Bone Miner Res **15:**120–128.
2. Bianco P, Robey PG, Wientroub S 2003 Fibrous dysplasia. In: Glorieux FH, Pettifor J, Juppner H (eds.) Pediatric Bone—Biology and Disease. Academic Press, New York, NY, USA, pp. 509–539.
3. Candeliere GA, Roughley PJ, Glorieux FH 1997 Polymerase chain reaction-based technique for the selective enrichment and analysis of mosaic arg201 mutations in G alpha s from patients with fibrous dysplasia of bone. Bone **21:**201–206.
4. Aldred MA, Trembath RC 2000 Activating and inactivating mutations in the human GNAS1 gene. Hum Mutat **16:**183–189.
5. Ragsdale BD, Sweet DE 1986 The pathology of incipient neoplasia. In: Henson E, Albores-Saavedra J (eds.) Bone. Saunders, Philadelphia, PA, USA, pp. 381–423.
6. Ragsdale BD 1993 Polymorphic fibro-osseous lesions of bone: An almost site-specific diagnostic problem of the proximal femur. Hum Pathol **24:**505–512.
7. Gilkey FW 1993 Liposclerosing myxofibrous tumor of bone. Hum Pathol **24:**1264.
8. Kransdorf MJ, Murphey MD, Sweet DE 1999 Liposclerosing myxofibrous tumor: A radiologic-pathologic-distinct fibro-osseous lesion of bone with a marked predilection for the intertrochanteric region of the femur. Radiology **212:**693–698.
9. Matsuba A, Ogose A, Tokunaga K, Kawashima H, Hotta T, Urakawa S, Umezu H, Higuchi T, Endo N 2003 Activating Gs alpha mutation at the Arg201 codon in liposclerosing myxofibrous tumor. Hum Pathol **34:**1204–1209.
10. Heim-Hall JM, Williams RP 2004 Liposclerosing myxofibrous tumour: A traumatized variant of fibrous dysplasia? Report of four cases and review of the literature. Histopathology **45:**369–376.
11. Murphey MD, Carroll JF, Flemming DJ, Pope TL, Gannon FH, Kransdorf MJ 2004 From the archives of the AFIP: Benign musculoskeletal lipomatous lesions. Radiographics **24:**1433–1466.
12. Lichtenstein L, Jaffe HL 1942 Fibrous dysplasia of bone. Arch Pathol **33:**777–816.
13. Shidham VB, Chavan A, Rao RN, Komorowski RA, Asma Z 2003 Fatty metamorphosis and other patterns in fibrous dysplasia. BMC Musculoskelet Disord **4:**20–27.
14. Alman BA, Greel DA, Wolfe HJ 1996 Activating mutations of Gs protein in monostotic fibrous lesions of bone. J Orthop Res **14:**311–315.
15. Sakamoto A, Oda Y, Iwamoto Y, Tsuneyoshi M 2000 A comparative study of fibrous dysplasia and osteofibrous dysplasia with regard to Gsalpha mutation at the Arg201 codon: Polymerase chain reaction-restriction fragment length polymorphism analysis of paraffin-embedded tissues. J Mol Diagn **2:**67–72.
16. Pollandt K, Engels C, Kaiser E, Werner M, Delling G 2001 Gsalpha gene mutations in monostotic fibrous dysplasia of bone and fibrous dysplasia-like low-grade central osteosarcoma. Virchows Arch **439:**170–175.

Address reprint requests to:
Paolo Bianco, MD
Dipartimento di Medicina Sperimentale e Patologia
Universita' La Sapienza
Viale Regina Elena 324
Rome 00161, Italy
E-mail: p.bianco@flashnet.it

Received in original form June 18, 2006; revised form August 8, 2006; accepted August 24, 2006.